

CASE REPORT

APPLICATION OF ULTRASOUND-GUIDED FEMORAL NERVE BLOCK IN A PATIENT WITH SEVERELY IMPAIRED LEFT VENTRICULAR FUNCTION UNDERGOING FEMORO-POPLITEAL BYPASS RECONSTRUCTIVE SURGERY

Trposka Poposka A.¹, Naumovski F.¹, Stojkowska Lozanovska A.¹, Kokareva A.¹, Andov M.², Anastasov M.²

¹University Clinic for Traumatology, Orthopedics, Anesthesia, Reanimation, Intensive Care and Emergency Department – Skopje, Department for Anesthesia, Reanimation and Intensive Care

²University Clinic for Thoracic and Vascular Surgery -Skopje, Department of Vascular Surgery

Abstract

Introduction:

Patients with severe left ventricular dysfunction undergoing major vascular surgery represent a high-risk population for perioperative morbidity and mortality. Careful anesthetic management focused on maintaining hemodynamic stability while minimizing myocardial depression is essential in such patients.

Case report:

We present the anesthetic management of an 84-year-old ASA IV patient with severely reduced left ventricular ejection fraction (35%), undergoing elective femoropopliteal bypass surgery due to critical peripheral arterial disease. The aim of this case report is to highlight the benefits of carefully titrated general anesthesia combined with an ultrasound-guided femoral nerve block and a low-dose dobutamine infusion to maintain stable hemodynamic conditions and reduce systemic opioid requirements, emphasizing an individualized anesthetic approach in a patient with complex cardiovascular and renal comorbidities. The block was performed using an in-plane ultrasound technique with bupivacaine and lidocaine. Throughout the entire procedure, the patient remained hemodynamically stable, without experiencing clinically significant episodes of hypotension, hypertension, arrhythmia, or tachycardia. The procedure lasted approximately 2 hours and 30 minutes and was completed without complications. The patient was extubated in the operating room, remained hemodynamically stable postoperatively, and was discharged from the hospital in stable condition.

Conclusion:

The use of peripheral nerve blocks in combination with general anesthesia may provide excellent conditions for performing complex vascular procedures in patients with cardiac comorbidities. Ultrasound-guided femoral nerve block combined with carefully titrated general anesthesia may represent a useful opioid-sparing strategy for maintaining hemodynamic stability in high-risk vascular patients with severe left ventricular dysfunction.

Keywords: *Femoral nerve block; left ventricular dysfunction; opioid-sparing anesthesia; regional anesthesia; vascular surgery.*

Introduction

Elderly patients with advanced cardiovascular disease undergoing major vascular surgery represent one of the highest-risk populations in anesthetic practice. Surgical treatment is associated with significantly increased perioperative cardiovascular complications and mortality compared with patients without cardiac disease (1). Patients with coexistence of severe left ventricular systolic dysfunction, impaired diastolic filling, and extensive atherosclerotic disease have a significantly increased risk for perioperative morbidity and mortality. Therefore, all these well-known facts require carefully tailored anesthetic management focused on maintaining hemodynamic stability and preserving myocardial function while avoiding exacerbation of pre-existing organ dysfunction. The goals of anaesthetic management in these patients undergoing major surgery include optimization of preload, maximization of forward flow, maintenance of stable hemodynamics, and prevention of potentially dangerous complications such as arrhythmias and acute on chronic heart failure (2). Achieving these goals requires careful titration of anesthetic agents and continuous hemodynamic monitoring. In such patients, even minor alterations in preload, afterload, heart rate, or myocardial contractility may lead to profound and significant hemodynamic instability, leading to clinically relevant end-organ hypoperfusion. General anesthesia in patients with severe heart failure is frequently associated with adverse hemodynamic effects, including myocardial depression, vasodilatation, and impaired autonomic regulation. Excessive use of systemic anesthetic agents and opioids may further compromise cardiac output and tissue perfusion. Regarding the risk of occurrence of all these well-known side effects with significant hazardous potential, multimodal and opioid-sparing anesthetic techniques have gained increasing importance in guiding high-risk patients with cardiovascular comorbidities (3). Therefore, strategies aimed at minimizing the use of myocardial depressant drugs while ensuring adequate analgesia and optimal surgical conditions have become modalities of particular interest and importance. Such a technique is the combination of general anesthesia with regional anesthetic techniques, which provides effective analgesia with reduced opioid requirements and improves perioperative hemodynamic stability in high-risk patients. The anesthetic management of patients with severe left ventricular dysfunction undergoing major vascular surgery represents a significant clinical challenge. In the present case, carefully titrated general anesthesia was combined with ultrasound-guided femoral nerve block and continuous low-dose inotropic support in order to maintain hemodynamic stability, reduce myocardial depression, and limit opioid use. This case highlights the importance of an individualized hemodynamic approach in the anesthetic management of high-risk vascular patients.

Case Report

This case report describes the anaesthetic management of an 84-year-old ASA IV patient with severe left ventricular dysfunction undergoing femoropopliteal bypass surgery. The aim of this case report is to highlight the benefits of a carefully titrated general anesthesia combined with an

ultrasound-guided femoral nerve block and a low-dose intraoperative inotropic support, emphasizing an individualized, opioid-sparing approach in a patient with complex cardiovascular and renal comorbidities. We present an 84-year-old female patient, 70 kg in weight and 160 cm in height, scheduled for elective lower limb revascularization surgery, where femoropopliteal bypass was the technique of choice due to critical peripheral arterial disease. According to the American Society of Anesthesiologists' physical status classification, our patient was classified as an ASA IV due to the presence of severe cardiovascular disease and multiple comorbidities. The patient's medical history was significant for advanced ischemic heart disease. She underwent coronary artery bypass grafting 22 years prior and had suffered an anterolateral myocardial infarction 10 years prior to the current admission. Her echocardiography findings have revealed dilated left ventricular chambers with segmental wall motion abnormalities, combined systolic and diastolic dysfunction, and a severely reduced left ventricular ejection fraction of approximately 35%. Additional comorbidities included chronic renal impairment with unilateral renal agenesis with preoperatively elevated urea levels (17.5 mmol/L) and creatinine concentration of 122 μ mol/L. The coagulation profile was within normal limits. Given the patient's advanced age, severe left ventricular dysfunction, renal impairment, and extensive cardiovascular history, a combined anesthetic approach was planned. The strategy consisted of carefully titrated general anesthesia combined with peripheral regional anesthesia to minimize myocardial depression, reduce opioid requirements, and preserve hemodynamic stability throughout the procedure. Prior to induction of general anaesthesia, invasive arterial blood pressure monitoring was established via radial arterial cannulation to allow continuous real-time assessment of hemodynamic parameters. Standard monitoring included electrocardiography, pulse oximetry, and capnography. A low-dose dobutamine infusion was initiated before induction and was titrated gradually depending on the patient's needs. Dobutamine infusion at 2 μ g/kg/min was initiated prior to induction and maintained at doses ranging from approximately 2 to 2.5 μ g/kg/min, providing inotropic support to maintain myocardial contractility. Induction of general anaesthesia was performed slowly and cautiously. The patient received midazolam 1 mg, fentanyl 50 μ g, ketamine 50 mg, propofol 30 mg, and cisatracurium 7 mg. Drug doses used for induction and intraoperative management were calculated based on the patient's actual body weight. Cisatracurium was chosen due to its organ-independent metabolism, particularly suitable in the presence of renal impairment. Tracheal intubation was achieved smoothly without significant fluctuations in arterial blood pressure or heart rate. Following induction and stabilization, a central venous catheter was inserted to enable central venous pressure monitoring and facilitate fluid and vasoactive drug administration. General anesthesia was maintained with sevoflurane at low concentrations, targeting a minimum alveolar concentration (MAC) of approximately 0.3, in combination with controlled ventilation. An ultrasound-guided femoral nerve block was performed on the operative side using a total volume of 15 mL, consisting of 7.5 mL of 0.5% bupivacaine and 7.5 mL of 2% lidocaine. The block was performed using a high-frequency linear ultrasound probe with an in-plane needle approach, allowing continuous visualization of the needle tip and accurate deposition of local

anesthetic adjacent to the femoral nerve. The block was administered to enhance intraoperative analgesia and to reduce the requirement for systemic anesthetic agents as part of an opioid-sparing strategy. During the surgical procedure, which lasted approximately 2 hours and 30 minutes, the patient received multimodal non-opioid analgesia, including metamizole and paracetamol. Additional medications administered as part of routine perioperative care included dexamethasone 8 mg, metoclopramide 10 mg, pantoprazole 40 mg, unfractionated heparin 5000 IU in line with surgical requirements, sodium bicarbonate 20 mL guided by arterial blood gas analysis, and furosemide 20 mg. Approximately 2500 mL of balanced crystalloid solution was administered intraoperatively in order to maintain adequate preload while avoiding fluid overload in a patient with reduced left ventricular function. Throughout the entire procedure, the patient remained hemodynamically stable, without experiencing clinically significant episodes of hypotension, hypertension, arrhythmia or tachycardia. Intraoperative mean arterial pressure ranged between approximately 80 and 100 mmHg, while heart rate ranged between 55 and 75 beats per minute. Arterial blood gas analysis demonstrated pH 7.32, pCO₂ 35 mmHg, and pO₂ 85.9 mmHg with lactate 2.62 mmol/L, without evidence of clinically significant tissue hypoperfusion. Intraoperatively, no additional opioids, or muscle relaxants were required after induction of anesthesia. At the end of surgery, neuromuscular blockade was reversed, and the patient was successfully extubated in the operating theater. She was awake, hemodynamically stable, and pain-free, with no evidence of residual motor blockade. The patient was transferred to the surgical ward for postoperative monitoring. Hemodynamic parameters remained stable, and no signs of myocardial ischemia, arrhythmia, or cardiac decompensation were observed. The patient did not require admission to the intensive care unit. Postoperative analgesia remained adequate during the first postoperative day without the need for opioid administration. The postoperative course was uneventful, and the patient was discharged from the hospital in stable condition.

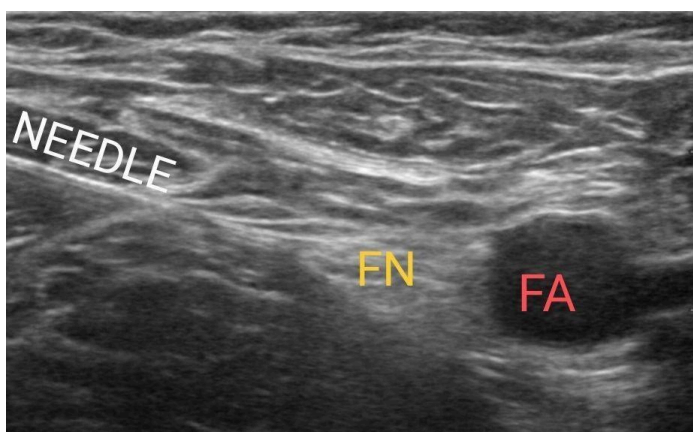


Figure 1. Ultrasound image demonstrating the femoral nerve (FN) adjacent to the femoral artery (FA) with in-plane needle visualization during ultrasound-guided femoral nerve block.

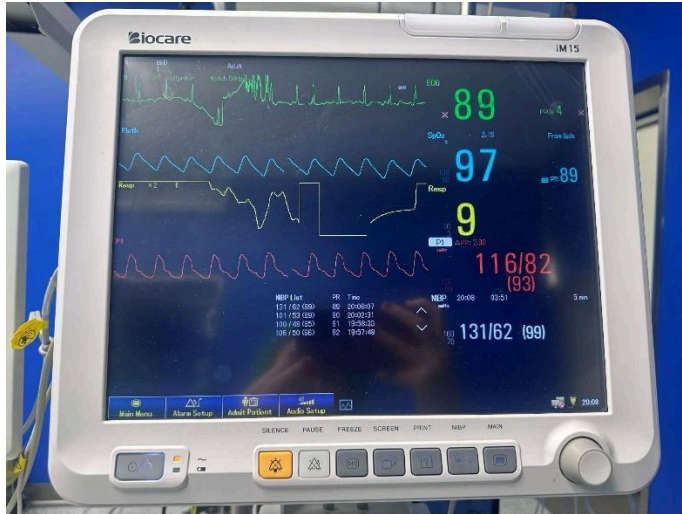


Figure 2. Representative intraoperative monitor display demonstrating stable hemodynamic parameters, including invasive arterial blood pressure and heart rate, during surgery under combined general and regional anesthesia.

Discussion

Vascular surgical techniques that involve open revascularization generally have a high risk of perioperative complications. Recent publications in the Macedonian Journal of Anesthesia have emphasized the importance of individualized perioperative management strategies in cardiac patients undergoing high-risk non-cardiac procedures, particularly in those with reduced left ventricular function (4). In this context, Garcia et al. identified the occurrence of perioperative complications in as many as 15.6% of patients with a 3.2% mortality rate (5). In another retrospective study, the occurrence of perioperative ischemic complications in patients undergoing vascular surgery was 11.4%, while the same authors detected not only increased morbidity in patients with cardiovascular disease, but also increased perioperative mortality of 6.4%, emphasizing the presence of cardiovascular disease as a significant risk factor for the development of serious perioperative complications and mortality (6). Hence, the two previous studies emphasize the severity of cardiovascular comorbidity as a significant risk factor for an unfavorable outcome of vascular surgical procedures even when all measures of precaution are considered. The above case completely fits into the category of patients analyzed in the studies of Garcia and Thomas, which indicate that anesthetic management can play a significant role in the occurrence or prevention of perioperative cardiovascular complications and mortality. Namely, the study of Thomas and colleagues determined that epidural analgesia, as a regional technique complementary to general anesthesia, does not have a favorable effect on the incidence of cardiovascular complications and mortality (6). Therefore, epidural analgesia was not applied in the presented case; instead, a safer regional anesthetic technique, such as the peripheral femoral nerve block, was selected as an alternative to neuraxial anesthesia. The safety of peripheral nerve blocks and their impact on perioperative morbidity and mortality were not analyzed in the above studies, but they may represent a safer alternative to neuraxial anesthesia,

as peripheral nerve blocks are not associated with significant reductions in peripheral vascular resistance or systemic vasodilation. According to Huttler et al., as many as 37% of patients undergoing major vascular surgery for peripheral arterial disease develop serious perioperative complications, while this percentage is significantly lower, at 19%, in patients with peripheral arterial disease undergoing minor vascular procedures (7). According to the aforementioned study, the surgical procedure performed on the patient presented in this paper is categorized as a major vascular surgery for peripheral arterial disease, with an exceptionally high risk of intra- and postoperative complications and mortality due to the presence of cardiovascular comorbidity. This fact justifies all the activities undertaken to reduce perioperative risk, including the use of invasive monitoring, continuous inotropic support from the very beginning of the procedure, and the application of peripheral nerve block as a regional technique aiming to reduce intraoperative consumption of opioids, hypnotics, and relaxants and thus ensuring hemodynamic stability. Echocardiographic findings that suggest the presence of elements of left ventricular failure as detected in the presented patient have been recognized and identified as a significant risk factor for postoperative complications in patients undergoing open vascular surgery (8).

The positive effects of regional anesthesia and peripheral nerve blocks have been recognized previously, with a reduced incidence of cardiovascular complications observed when peripheral nerve blocks are used compared with neuraxial anesthesia (9). Hence, their use before neuraxial anesthesia is clearly defined and included in European recommendations when guiding patients with cardiovascular comorbidities for non-cardiac surgery. In this regard, this paper presents the effect of the use of the peripheral femoral nerve block and its analgesic properties in cardiac-compromised patients, which is observed through the creation of ideal working conditions for the surgeon, with reduced systemic use of drugs. The hemodynamic stability of the patients and the reduced incidence of cardiovascular events in the perioperative period are most likely due to the lower stress response and the reduced or completely extinguished activation of the sympathetic nervous system during the application of peripheral nerve blocks in patients with cardiovascular comorbidities (9). This finding supports the use of ultrasound-guided femoral nerve blocks in routine clinical practice when performing vascular procedures on the peripheral arteries of the lower limb. The usefulness of peripheral nerve blocks in patients with existing cardiac pathology has also been seen in the meta-analysis of Memtsoudis and colleagues, where after analyzing 122 studies, a significantly lower incidence of cardiac complications in the perioperative period was observed, compared with patients where only general anesthesia was applied (10).

Knowledge regarding the effects of peripheral nerve blocks on the sympathetic nervous system compared with neuraxial anesthesia suggests that they may represent a safer option in patients with cardiovascular comorbidities, as peripheral nerve blocks do not cause a decrease in peripheral vascular resistance and systemic vasodilation. Peripheral nerve blocks may offer important advantages over neuraxial anesthesia in patients with significant cardiovascular comorbidities, as they are not associated with pronounced sympathetic blockade and sudden decreases in peripheral vascular resistance. This ability may be particularly beneficial in patients

with severe left ventricular dysfunction, where maintaining stable hemodynamic conditions is essential. In such patients, even minor reductions in systemic vascular resistance or myocardial contractility may lead to significant hemodynamic instability and impaired end-organ perfusion, which highlights the importance of carefully titrated anesthetic techniques. Furthermore, the use of regional anesthesia contributed to an opioid-sparing anesthetic strategy, which may further support hemodynamic stability and reduce perioperative stress response in high-risk vascular patients. Hence, the choice of this technique, where general anesthesia is supplemented with regional anesthesia, was not only a personal choice of the attending anesthesiologists, but an approach supported by evidence-based medicine and recommendations from contemporary guidelines for the treatment of patients with cardiac pathology in non-cardiac surgery.

Conclusion

The use of peripheral nerve blocks in combination with general anesthesia can create excellent conditions for performing complex vascular procedures in patients with cardiac comorbidities. Namely, the absence of significant hemodynamic destabilization in an already cardiovascularly-compromised patient indicates the safety of the peripheral femoral nerve block, which can serve as a tool to reduce the systemic use of anesthetics. Ultrasound-guided femoral nerve block can and should be used in everyday anesthetic practice as a regional anesthetic technique complementary to general anesthesia during peripheral arterial reconstructive procedures of the lower limb. This case highlights the potential benefits of combining ultrasound-guided peripheral nerve blocks with carefully titrated general anesthesia in high-risk vascular patients with severe left ventricular dysfunction.

Ethical approval: This case report contains fully anonymized patient data and does not include any identifiable patient information. Ethical approval was not required for publication of a single case report according to institutional regulations.

Consent for publication: Written informed consent was obtained from the patients prior to inclusion in the study.

Conflict of interest: The authors declare that they have no conflict of interest.

Funding: This research received no external funding.

Author contributions: All authors contributed to the conception of the work, data collection, manuscript preparation, and approved the final version of the manuscript.

Use of Artificial Intelligence (AI) tools: The authors declare that no artificial intelligence tools were used in the preparation of this manuscript.

Acknowledgments: None.

References:

1. Kristensen SD, Knuuti J, Saraste A, et al. 2014 ESC/ESA Guidelines on non-cardiac surgery: cardiovascular assessment and management. *Eur Heart J*. 2014;35(35):2383-2431. doi:10.1093/eurheartj/ehu282.
2. Mittal AK, Chowdhury I, Arora M, Jain CR. Anesthetic management of a patient with heart failure and reduced ejection fraction for radical cholecystectomy with liver resection surgery. *Indian Anaesthetists Forum*. 2017;18(1):19-22. doi:10.4103/TheIAForum.TheIAForum_5_17.
3. Kehlet H, Dahl JB. Anaesthesia, surgery, and challenges in postoperative recovery. *Lancet*. 2003;362(9399):1921-1928
4. Brzanov-Gavrilovska A, Chavkoska M, Petrusheva-Panovska M, Jovanovski-Srceva M, Shosholcheva M. Non-cardiac surgery in cardiac patients: key insights. *Maced J Anaesth*. 2025;9(1):55-62. doi:10.55302/MJA259155gb.
5. Garcia S, Moritz TE, Goldman S, Littooy F, Pierpont G, Larsen GC, et al. Perioperative complications after vascular surgery are predicted by the revised cardiac risk index but are not reduced in high-risk subsets with preoperative revascularization. *Circ Cardiovasc Qual Outcomes*. 2009;2(2):73-79. doi:10.1161/CIRCOUTCOMES.108.827683.
6. Thomas D, Sharmila S, Saravana Babu MS, Raman SP, Gadhinglajkar SV, Koshy T. Perioperative cardiovascular outcome in patients with coronary artery disease undergoing major vascular surgery: a retrospective cohort study. *Ann Card Anaesth*. 2022;25(3):297-303. doi:10.4103/aca.aca_88_21.
7. Huttler JJ, Satam KK, Kim TI, Zhuo H, Zhang Y, Aboian E, et al. Perioperative complications of minor and major reinterventions for peripheral arterial disease. *Vascular*. 2025;33(2):446-455. doi:10.1177/17085381241246907.
8. Bolognesi R, Tsialtas D, Bolognesi MG, Assimopoulos S, Azzarone M, Volpi R. Perioperative complications following major vascular surgery: correlations with preoperative clinical, electrocardiographic and echocardiographic features. *Acta Biomed*. 2022;93(3):e2022255. doi:10.23750/abm.v93i3.12961.
9. Marchertiene I. Regional anesthesia for patients with cardiac diseases. *Medicina (Kaunas)*. 2003;39(8):721-729.
10. Memtsoudis SG, Cozowicz C, Bekeris J, Bekere D, Liu J, Soffin EM, et al. Peripheral nerve block anesthesia/analgesia for patients undergoing primary hip and knee arthroplasty: recommendations from the ICAROS group. *Reg Anesth Pain Med*. 2021;46(11):971-985. doi:10.1136/rapm-2021-102750.