

ORIGINAL ARTICLE

DISTINCT MRI PHENOTYPES OF NEUROGENIC VS. NON-NEUROGENIC CERVICOBRACHIAL PAIN: A COMPARATIVE STUDY

Janevski P.¹, Nikolova S.¹, Daskalov D.¹, Jakimovska Dimitrovska M.¹, Bundovska Kocev S.¹, Veljanovski D.²

¹University Institute of Radiology, Medical Faculty, "Ss Cyril and Methodius" University, Skopje, Republic of North Macedonia.

²Department of Radiology, General City Hospital "8-mi Septemvri" Skopje, Republic of North Macedonia

Abstract

The differentiation of cervicobrachial pain into neurogenic and non-neurogenic etiology, is crucial for appropriate clinical management. A clear distinction based on objective findings can guide therapeutic strategies. The goal of this paper is to compare the demographic, anamnestic and magnetic resonance imaging (MRI) characteristics between patients with neurogenic and non-neurogenic cervicobrachial pain. This analytical, cross-sectional study included 130 patients with symptoms of cervicobrachial syndrome referred to cervical spine MRI. Based on radiological findings of nerve root or spinal cord compression, patients were divided into a neurogenic pain group (n=85) and a non-neurogenic pain group (n=45). Demographic and anamnestic data were collected via a questionnaire. Statistical analysis was performed using Student's t-test and the X²-test. The non-neurogenic pain group was significantly younger than the neurogenic group (mean age 39.0±13.5 vs. 46.5±12.9 years, p=0.0023). The history of a motor vehicle accident (MVA) was significantly more frequent in the neurogenic group (23.5% vs. 4.4%, p=0.0058). Advanced degenerative findings, such as spondylosis (58.8% vs. 4.4%, p<0.0001) and Modic changes (14.1% vs. 2.2%, p=0.031), were significantly more prevalent in the neurogenic group. Conversely, isolated disc dehydration was significantly more common in the non-neurogenic group (81.2% vs. 48.9%, p=0.00013). In conclusion, neurogenic and non-neurogenic cervicobrachial pain exhibit distinct demographic and radiological profiles. Neurogenic pain is associated with older age, a history of trauma and advanced degenerative changes. Non-neurogenic pain is more characteristic in younger patients, predominantly female, and is associated with early degenerative findings like disc dehydration.

Key Words: *Cervicobrachial Syndrome, Degenerative Disc Disease, Magnetic Resonance Imaging (MRI), Neurogenic Pain, Spondylosis.*

Introduction

Neck pain, often radiating to the arm as cervicobrachial syndrome, represents a major global health burden, with a point prevalence estimated to be as high as 20% in the adult population, leading to significant disability and economic cost (1). While its pathogenesis is often attributed to cervical radiculopathy from disc herniation, clinical practice reveals a more complex picture. Many patients suffer from debilitating pain without clear radiological evidence of neural impingement, creating diagnostic and therapeutic challenge.

This challenge underscores the need to differentiate the etiology of pain into two broad categories: neurogenic and non-neurogenic. Neurogenic pain is the direct consequence of mechanical or inflammatory irritation of neural structures, typically from disc herniation or osteophytes causing spinal or foraminal stenosis (2). In contrast, non-neurogenic pain arises from other anatomical sources. This includes pain originating from the zygapophyseal (facet) joints, ligaments, muscles or the intervertebral disc itself - a condition known as discogenic pain (3, 4). Discogenic pain is thought to be caused by nociceptive stimulation within the annulus fibrosus of a structurally compromised disc, even in the absence of nerve root compression (5).

Distinguishing between these etiologies is crucial, as it directly guides management. Neurogenic pain may require interventional or surgical approaches, whereas non-neurogenic pain is primarily treated with conservative measures like physical therapy and pharmacotherapy. This distinction is not only critical for surgeons and physical therapists but also for anesthesiologists specializing in pain management, as an accurate etiological diagnosis is paramount for the success of interventional procedures such as cervical epidural steroid injections or nerve root blocks. Magnetic Resonance Imaging (MRI) is the gold standard for visualizing cervical spine anatomy, yet its findings often correlate poorly with clinical symptoms (6). Given the high prevalence of degenerative findings in asymptomatic individuals, simply identifying a pathological finding is often insufficient (7). Therefore, stratifying symptomatic patients based on the presumed pain generator (neurogenic vs. non-neurogenic) may offer a more clinically relevant approach to understand the source of pain.

Therefore, the aim of this study was to perform a comparative analysis of the demographic, anamnestic and detailed MRI findings in patients with symptomatic cervicobrachial pain, classified by a neurogenic versus non-neurogenic etiology, in order to identify distinct patients' phenotypes and contribute to a better understanding of the underlying pathophysiology.

Materials and Methods

This analytical, cross-sectional study was conducted at the University Institute of Radiology in Skopje. The study included 130 patients, aged 18 to 80 years, with a working diagnosis of cervicobrachial syndrome or cervical radiculopathy. Exclusion criteria were age under 18 or over 80 years, pain of somatic origin due to neoplastic changes or spondylodiscitis, prior cervical spine surgery and pain lasting less than two weeks. All participants provided informed consent.

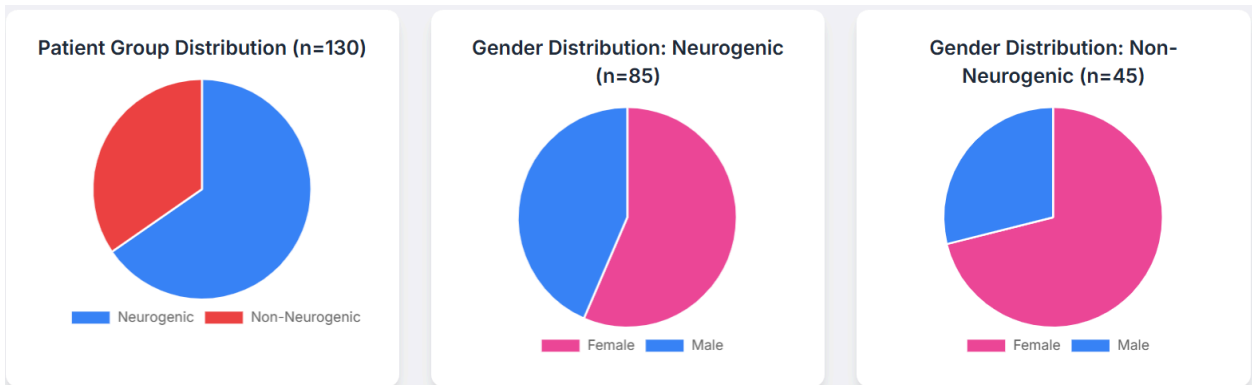
All patients underwent an MRI examination on a 1.5T Magnetom Essenza system (Siemens). Standard protocols included T1-weighted and T2-weighted pulse sequences in sagittal and axial planes, as well as a T2-weighted sequence with fat suppression in the sagittal plane. Prior to the examination, each participant completed a questionnaire to collect demographic and anamnestic data.

Based on the radiological findings, patients were stratified into two groups: 1. Neurogenic Pain Group (n=85): Patients with MRI evidence of spinal and/ or neuroforaminal stenosis caused by disc herniation or a posterior disc-osteophyte complex, resulting in visible compression or displacement of the spinal cord or nerve roots that correlated with the clinical presentation. 2. Non-Neurogenic Pain Group (n=45): Patients with clinical symptoms but without radiological evidence of significant neural compression.

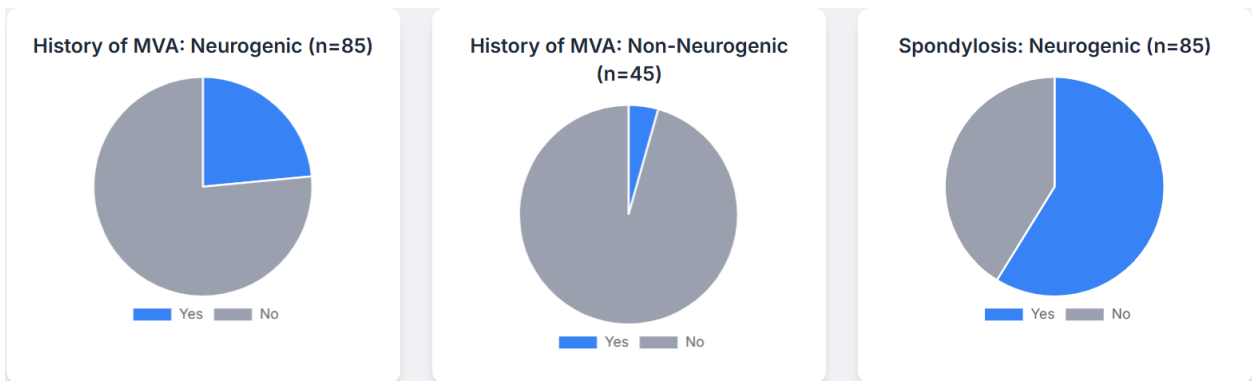
Statistical analysis was performed using SPSS 23.0. A Student's t-test was used to compare continuous variables (age), and the X²-test was used for categorical variables (gender, presence/ absence of findings). A p-value of <0.05 was considered statistically significant.

Results

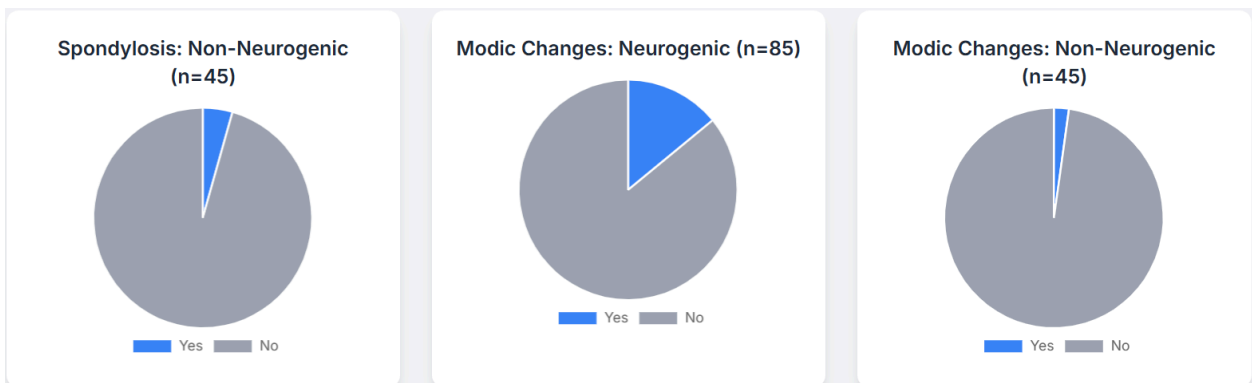
Out of the 130 participants, 85 (65.4%) were classified into the neurogenic pain group, and 45 (34.6%) into the non-neurogenic pain group. Patients with non-neurogenic pain were significantly younger, with a mean age of 39.0±13.5 years, compared to 46.5±12.9 years in the neurogenic group (t=3.11, p=0.0023). Although not statistically significant, there was a higher proportion of females in the non-neurogenic group (71.1% vs. 56.5% in the neurogenic group, p=0.1).



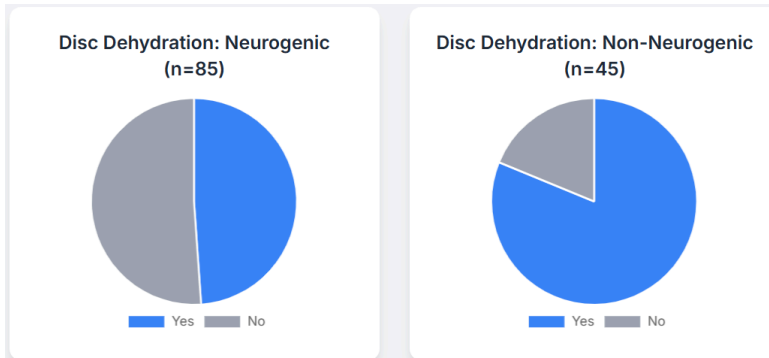
A history of a prior motor vehicle accident (MVA) was reported with a significantly higher frequency by patients in the neurogenic pain group (23.5%) compared to the non-neurogenic group (4.4%) ($X^2=7.62$, $p=0.0058$).



The comparison of MRI findings revealed significant differences. Cervical spondylosis was diagnosed in 50 (58.8%) patients with neurogenic pain, but in only 2 (4.4%) patients with non-neurogenic pain, a highly significant difference ($X^2=36.25$, $p<0.0001$). Similarly, Modic changes, representing vertebral endplate pathology, were detected in 12 (14.1%) patients with neurogenic pain, compared to only 1 (2.2%) patient with non-neurogenic pain ($p=0.031$) (8).



Disc dehydration, as an early degenerative finding, was significantly more common in patients with non-neurogenic pain (81.2%) than in those with neurogenic pain (48.9%) ($X^2=14.61$, $p=0.00013$). The prevalence of facet arthropathy did not show a statistically significant difference between the groups (24.7% in the neurogenic group vs. 17.8% in the non-neurogenic group, $p=0.37$).



Discussion

Our study reveals that neurogenic and non-neurogenic cervicobrachial pain are not merely different points on a single degenerative continuum but rather represent two distinct clinicopathological entities. The non-neurogenic profile represents the initial stage of the degenerative cascade, driven by internal disc disruption, while the neurogenic profile signifies the end-stage of this process, characterized by structural compression and often accelerated by prior trauma.

The first phenotype, non-neurogenic pain, is characteristic of a younger, predominantly female demographic. The cornerstone radiological finding in this group was a high prevalence of disc dehydration. This strongly suggests that the pain source is primarily discogenic, arising from internal disc disruption rather than external neural compression. As the disc dehydrates, it loses its hydrostatic pressure and mechanical integrity, leading to the development of annular fissures. These fissures can allow inflammatory mediators from the nucleus pulposus to leak into the richly innervated outer annulus, stimulating nociceptors and generating pain.

In stark contrast, the neurogenic pain phenotype is associated with an older patient population where the degenerative cascade is far more advanced. The significantly higher prevalence of spondylosis and Modic changes in this group points to a long-standing process of biomechanical failure and instability. Spondylosis, characterized by osteophyte formation, directly narrows the spinal canal and neural foramina, leading to mechanical compression. Modic changes, particularly Type 1, are now understood to represent an active inflammatory and edematous process in the vertebral endplate, often associated with segmental instability

and severe pain (8). Our findings show a particular concentration of these advanced changes at the C5-C6 level, which is consistent with biomechanical studies identifying this segment as the apex of cervical lordosis and the zone of greatest flexion-extension motion, thus subjecting it to maximal mechanical stress (9).

A pivotal finding from our study is the strong association between the history of MVA (whiplash) and the development of neurogenic pain. Our findings support the hypothesis that trauma may act as an "initiator" or "accelerator" of the degenerative cascade (10). Whiplash injuries can cause occult microfractures of facet joints and vertebral endplates, leading to chronic low-grade inflammation, ligamentous laxity and segmental instability. Over time, this instability promotes the accelerated development of spondylosis and disc herniation, ultimately culminating in the neurogenic compression seen in our older cohort (11, 12).

This study has several limitations. Its cross-sectional design allows us to identify associations but not to establish causality. The sample size is relatively modest, and the unequal group sizes may limit statistical power. As a single-center study, the results may have limited generalizability. Furthermore, the reliance on a patient's questionnaire for anamnestic data introduces the possibility of recall bias. Crucially, we did not include an asymptomatic control group. It is well-documented that degenerative findings are highly prevalent in the pain-free population, which complicates the direct attribution of any single finding as the definitive cause of pain (7).

Conclusion

In conclusion, this study demonstrates that neurogenic and non-neurogenic cervicobrachial pain are associated with distinct and recognizable patient profiles. Non-neurogenic pain is primarily a condition in younger individuals, linked to early discogenic changes. Neurogenic pain is a manifestation of advanced, multi-faceted degenerative disease in an older population, often accelerated by prior trauma. This etiological stratification, guided by careful synthesis of patient's history and targeted MRI analysis, provides a more nuanced pathophysiological framework that can empower clinicians to select more precise and effective therapeutic strategies, ultimately improving patients' outcomes.

References:

1. Hogg-Johnson S, van der Velde G, Carroll LJ, et al. The burden and determinants of neck pain in the general population: results of the Bone and Joint Decade 2000-2010 Task Force on Neck Pain and Its Associated Disorders. *Spine (Phila Pa 1976)*. 2008;33(4 Suppl):S39-51.
2. Rao RD, Currier BL, Albert TJ, et al. Degenerative conditions of the cervical spine: radiculopathy and myelopathy. *J Bone Joint Surg Am*. 2007;89(6):1360-78.

3. North American Spine Society. Clinical Guidelines for Multidisciplinary Spine Care: Diagnosis and Treatment of Cervical Radiculopathy from Degenerative Disorders. 2010.
4. Gellhorn AC, Katz JN, Suri P. Osteoarthritis of the spine: the facet joints. *Nat Rev Rheumatol*. 2013;9(4):216-24.
5. Bogduk N. The anatomy and pathology of discogenic pain. *Neurosurgery Quarterly*. 2009;19(2):88-100.
6. Hills MW, Deane SA. Head injury and facial injury: is there an increased risk of cervical spine injury? *J Trauma*. 1993;34(4):549-50.
7. Brinjikji W, Luetmer PH, Comstock B, et al. Systematic literature review of imaging features of spinal degeneration in asymptomatic populations. *AJNR Am J Neuroradiol*. 2015;36(4):811-6.
8. Zhang YH, Zhao CQ, Jiang LS, et al. Modic changes: a systematic review of the literature. *Eur Spine J*. 2008;17(10):1289-1299.
9. Davis C. Chiropractic treatment in the management of cervical spine problems: a literature review. *J Manipulative Physiol Ther*. 2001;24(6):353-61.
10. Freeman MD, Rosa S, Harshfield D, et al. A case-control study of cerebellar tonsillar ectopia (Chiari) and head/neck trauma (whiplash). *Brain Injury*. 2010;24(7-8):988-94.
11. Köhler BM, Günther J, Kaudewitz D, et al. Facet joint osteoarthritis: a review of current concepts. *Curr Treat Options Rheumatol*. 2020;6:1-12.
12. Kovalova I, Kerkovsky M, Kadanka Z, et al. Prevalence of cervical spine abnormalities in patients with multiple sclerosis and their effect on disability. *Spine (Phila Pa 1976)*. 2016;41(24):1908-16.